



More than Skin Deep: Shock in a Pediatric Patient with Scald Burn

Mariann Nocera Kelley, MD


May 15, 2026

17 month old unknown female presented with
burn and altered mental status


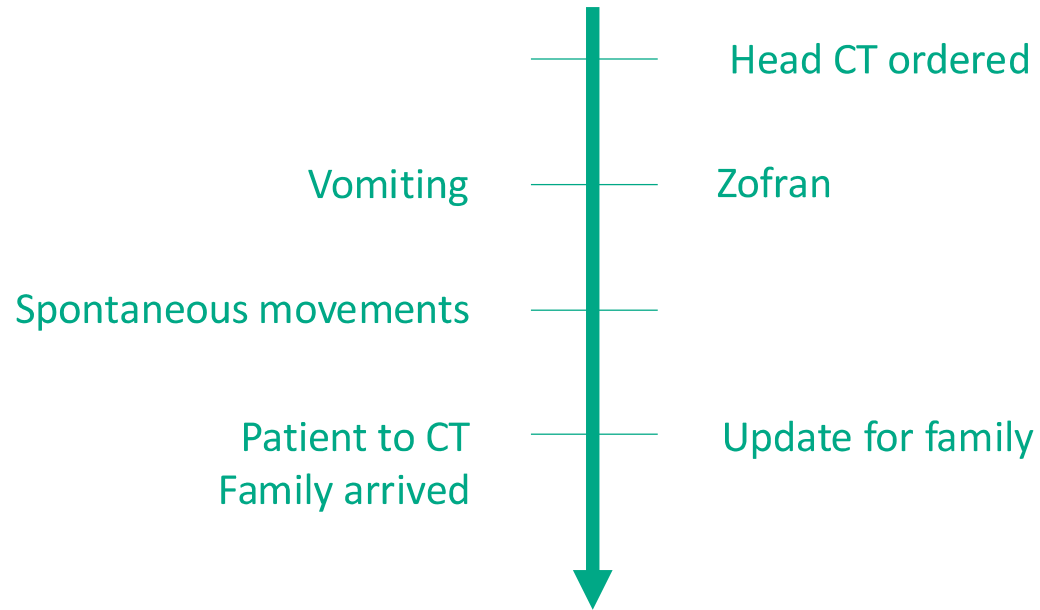
EMS found her unresponsive with decreased respirations. She required brief BMV though she had some spontaneous respirations. IO placed.

Mother lost consciousness en route to the ED

Primary Surey



Case Continued



Case Continued



HR improved to 150s
Remains hypotensive

HR 157, BP 109/64

Crackles in bilateral lung bases

Hemoglobin: 5.9

Carboxyhemoglobin: 13.8%

FAST: concerning for free fluid in the RUQ

IM epinephrine

IM epinephrine #2
Epinephrine infusion

Unasyn

MTP
100% oxygen
Abdominal CT

Admit to PICU

Anaphylactic shock 2/2 transdermal exposure



PAI
PEDIATRIC ALLERGY
AND IMMUNOLOGY



Correspondence

A child with anaphylactic reaction by egg remedy applied to burn

Eirini Roumpedaki , Nikolaos Douladiris, Anna Papanaki, Lela Stamogiannou, Paraskevi Maggina, Emmanuel Manoussakis, Gerasimina Vallianatou, Nikolaos G. Papadopoulos, Paraskevi Xepapadaki

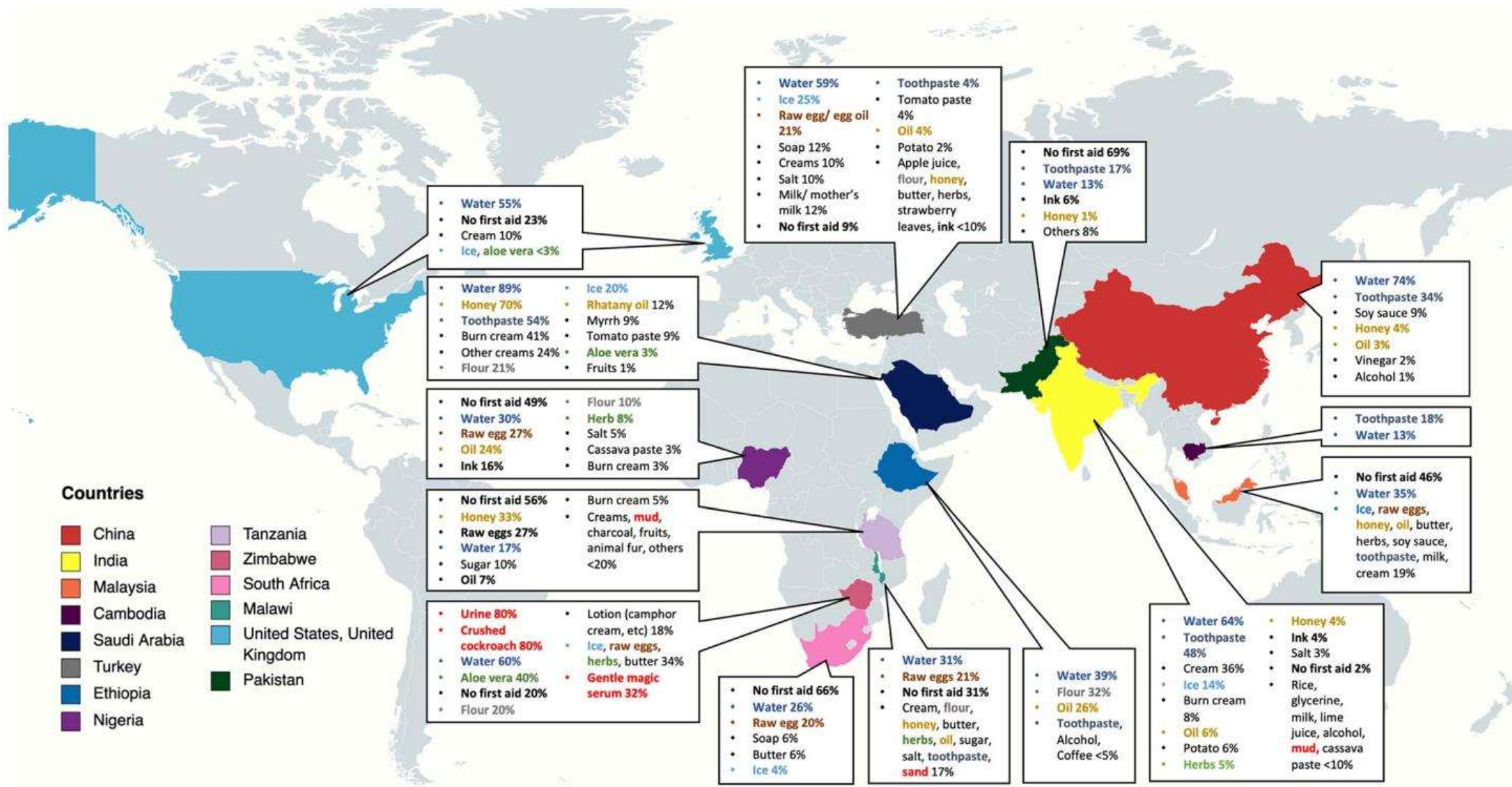
Journal of
EMERGENCY NURSING




PEDIATRIC UPDATE · Volume 32, Issue 3, P274-276, June 2006

Pediatric Anaphylaxis: Allergic Reaction to Egg Applied to Burns

Shauna Hansen, RN, BSN · Nancy Mecham, APRN, FNP  



Burn first aid



Questions?